

The Patient Perspective

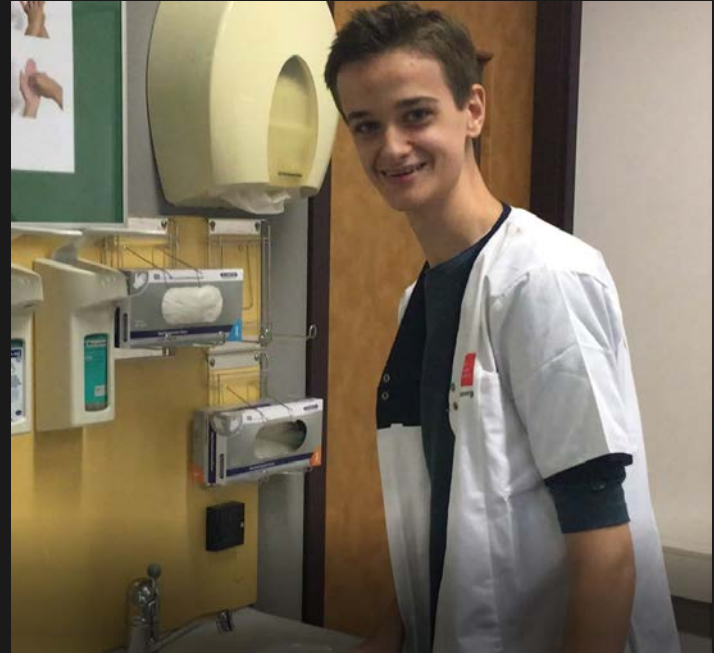Tijmen Wolbers
The Netherlands

General Information

Tijmen Wolbers
The Netherlands
Aged 21

4th year student
Secondary
Vocational
Education (MBO)
nursing.

Diagnosed with VHL
in 2016



2017, 1st year student

Prologue

- Healthy
- No medical issues
- No diagnosis or hint VHL

- Aged 11 during cycling I noticed formation on the epididymis.
- Local hospital → UMC Wilhelmina Children's Hospital.
- Surgically removed

Results

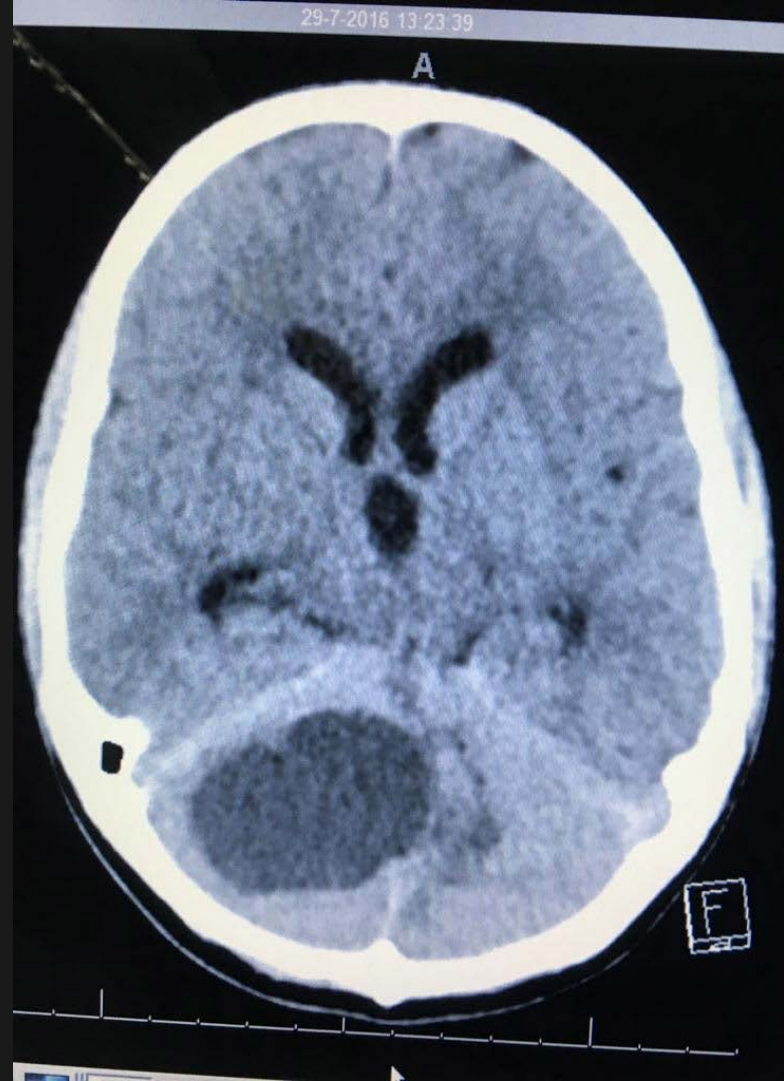- **Single Echo** of both my kidneys.
- Informed by urologist there is a slim chance a cyst could also appear in the kidneys.
- Clean result, without any further information sent home.
- Pathologist wrote down on his report **"VHL?"**



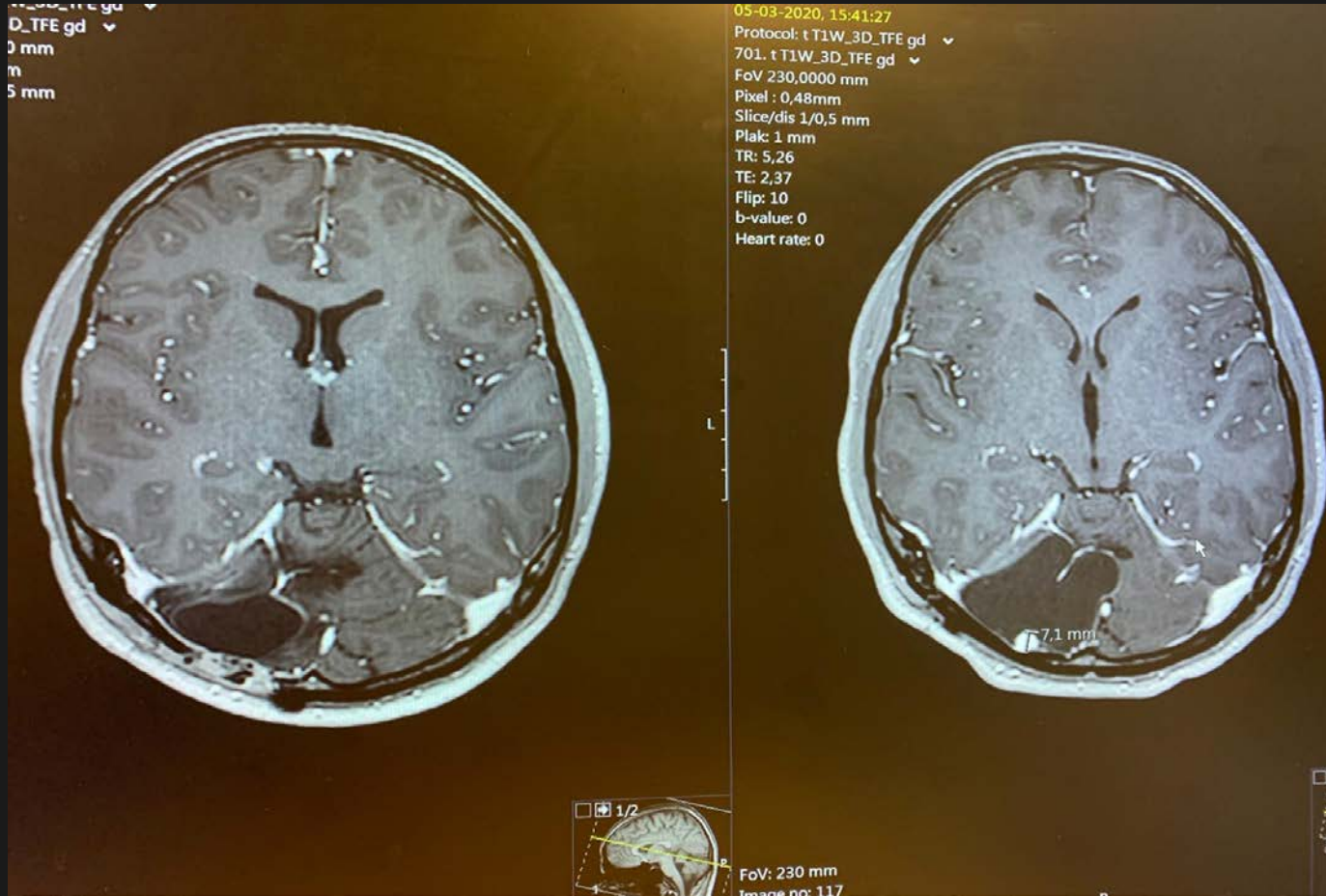
2016, United States

Signs & Symptoms

- Lack of appetite
- Headaches
- Vomiting when waking up
- Persistent dizziness
- Increase in symptoms when changing body / head position
- Unable to walk in a straight line
- Difficult to maintain balance



2nd Hemangioblastoma in cerebellum 2020



Direct contact




- UMC Utrecht
- Specialised nurse
- Intermediary between treating doctors and patient
- Medical Issues → Forward to the appropriate doctors / departments



**Interest group
Von Hippel-Lindau
Netherlands**

- **Contact with other patients**
- **Yearly meetings**
 - **Presentations from Dutch doctors and engineers related to VHL, surgeries ect.**
- **International contact with other VHL interest groups**
- **Sharing information**
- **E-mail or contact via phone**

VHL International Youth Symposium



Q&A